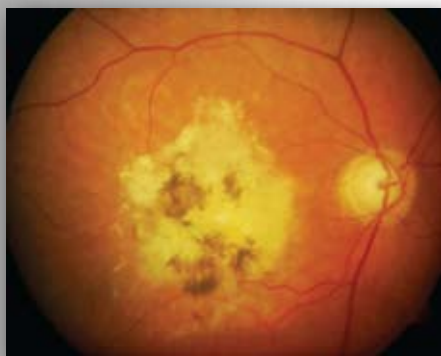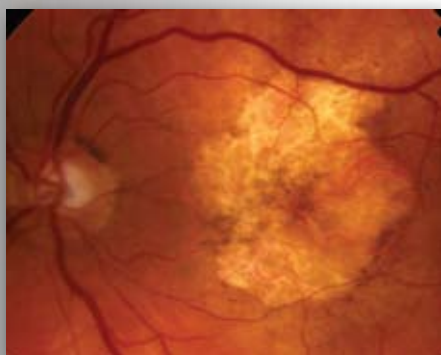


Advanced AMD

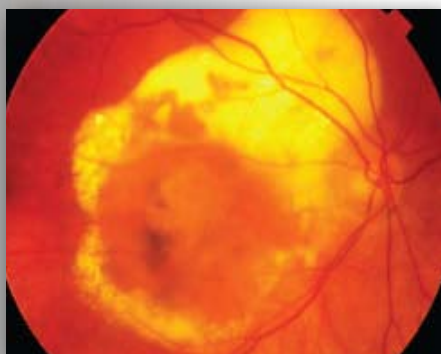
Refer if fulfils guidelines on form



Disciform Scar: Extensive subretinal fibrosis and pigment change at the macula. This shows advanced disease.



Geographic atrophy: Another form of advanced AMD (Dry) showing extensive retinal atrophy / thinning at the macula.



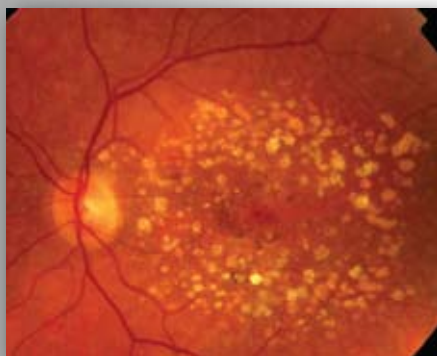
Advanced wet AMD - central macular elevation with/without subretinal fluid, hard exudate and some fibrosis.

If best corrected visual acuity is worse than 6/96, these patients may require a hospital assessment on a non-urgent basis.

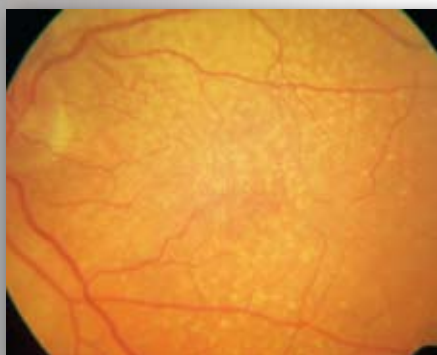
They may benefit from LVA assessment, visual impairment counselling and/or registration.

Drusen

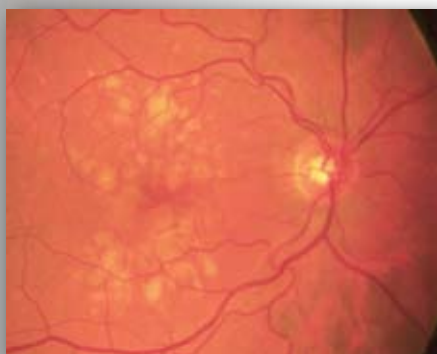
Refer only if fulfils guidelines on form



Multiple drusen and pigment change.



Multiple fine hard drusen.



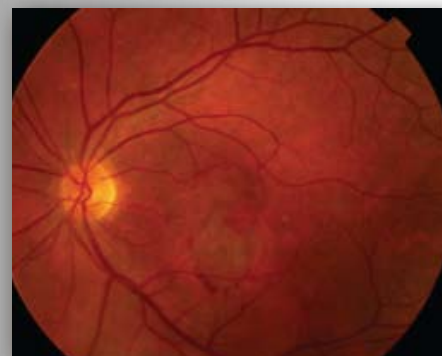Large soft drusen.

These appearances are consistent with Age Related Maculopathy (ARM). Patients with drusen commonly notice distortion when shown an Amsler grid. This is less significant than spontaneously reported visual distortion.

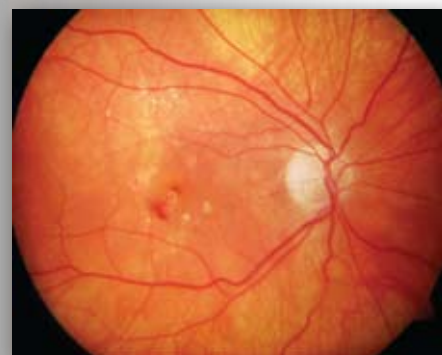Only refer if patient has noticed sudden onset of distortion or blurring of central vision. If the patient smokes they should be encouraged to give up as smoking has been shown to be a risk factor in the development of AMD. These patients may benefit from ocular nutritional supplements.

Wet AMD

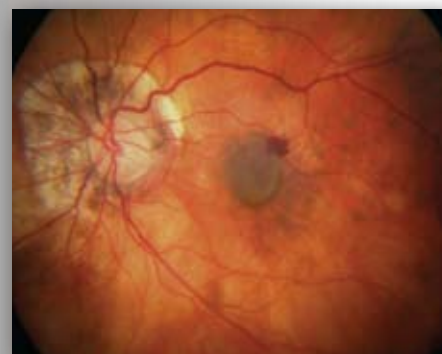Refer if fulfils guidelines on form



Subretinal haemorrhage and subretinal fluid suggest choroidal neovascularisation. This patient requires urgent referral and assessment.



Intraretinal haemorrhage centrally and exudates deposition superiorly. There may be associated subtle subretinal fluid or thickening. The presence of exudates is an important sign of leakage from choroidal neovascularisation. Refer urgently.



Small areas of intra / sub retinal haemorrhage amongst the drusen suggest choroidal neovascularisation. This patient requires urgent referral and assessment.

Blood, retinal swelling and exudates deposition at the macula suggest wet AMD requiring urgent referral.

Please refer according to local protocols or use the attached form and fax to the appropriate consultant.

WET AMD RAPID ACCESS REFERRAL FORM

Name of Consultant: St Paul's Primary Care
Fax Number: Phone: 0151-706-3949
Fax: 0151-706-5624

PATIENT DETAILS

NAME : _____ DOB : _____ HOSPITAL NO: _____
(If known)
ADDRESS : _____
CONTACT TEL NOS : _____

GP NAME: _____ **GP SURGERY:** _____

OPTOMETRIST DETAILS (please print, do not use a stamp)

NAME : _____ PRACTICE : _____
GOC NO: _____ ADDRESS: _____
TEL : _____ FAX : _____

AFFECTED EYE : RIGHT LEFT

PAST HISTORY IN EITHER EYE

PREVIOUS AMD RIGHT LEFT
MYOPIA RIGHT LEFT
OTHER _____ RIGHT LEFT

Referral Guidelines

PRESENTING SYMPTOMS IN AFFECTED EYE (one answer must be 'yes')

Duration of visual loss:

Please specify _____

1. Visual loss YES NO
2. Spontaneously reported distortion YES NO
3. Onset of scotoma (or blurred spot) in central vision YES NO

FINDINGS Best corrected VA (must be 6/96 or better in affected eye)

1. Distance VA RIGHT / LEFT /
2. Near VA RIGHT LEFT
3. Macular drusen (either eye) RIGHT LEFT

In the affected eye ONLY, presence of:

4. Macular haemorrhage (preretinal, retinal, subretinal) YES NO
5. Subretinal fluid YES NO
6. Exudate YES NO

Comments

